



Molecular and Histopathological Study of *Sarcocystis* spp. Parasites Infecting Selected Species of Local Birds in Al-Diwaniyah Governorate / Iraq

Hayder Akriem Muslim^{1*}, Khaled Thamer Alshaebani¹

¹Department of Biology, College of Education, University of Al-Qadisiyah, Al-Qadisiyah, Iraq

Abstract

Introduction: *Sarcocystis* is a globally widespread parasite that has garnered increasing attention in recent years due to its health and economic impacts. It is a significant parasitic disease that contributes to neurological disorders in infected animals and causes substantial economic losses in livestock production.

This study aimed to detect *Sarcocystis* infection in wild pigeons, domestic chickens, and ducks in Al-Diwaniyah Governorate using macroscopic, microscopic, and molecular examinations. The study also evaluated the influence of infection-related factors and the efficacy of different diagnostic methods.

Methods: The study examined 150 birds between October 2025 - March 2026, 50 of each species. Diagnosis was based on comparisons of macroscopic and microscopic examinations using three methods (pepsin digestion, slide crushing, and garlic press), Nested-PCR targeting the 18S rRNA gene, and histological examinations.

Results: Gross examination showed an overall infection rate of 6%, whereas microscopic examination revealed a higher rate of 32%, confirming its superior sensitivity and diagnostic efficiency. The pepsin digestion method was particularly effective compared to slide-crushing, crushing, and garlic-pressing methods. Wild pigeons exhibited the highest infection rates, with the esophagus being the most frequently affected organ. Statistically, the analyses did not show significant differences in infection rates by bird sex, time of year, or geographic region, despite higher infection rates in winter. Nested-PCR confirmed positive infections at 622 base pairs. Genetic analysis identified *Sarcocystis columbae* in wild pigeons, *Sarcocystis wenzeli* in domestic chickens, and *Sarcocystis rileyi* in ducks. Histological examinations revealed parasitic cysts within muscle fibers, accompanied by inflammatory changes and cellular infiltration.

Conclusion: This study concludes that microscopic examination using pepsin digestion is the most efficient and reliable diagnostic tool in conventional laboratories. At the same time, molecular and genetic analysis remains the cornerstone for accurate qualitative classification of parasite isolates. These results highlight the critical importance of integrating microscopic, histological, and molecular examinations to ensure a comprehensive and accurate diagnosis of *Sarcocystis* in birds.

Keywords: *Sarcocystis* spp., Birds, 18S rRNA gene, phylogenetic analysis, Al-Diwaniyah.

Received: April 16, 2026, Revised: May 12, 2026, Accepted: May 27, 2026, ePublished: June 29, 2026

Introduction

Sarcocystis is widespread globally and has received increasing attention in recent years due to its health and economic impacts. It is a significant parasitic disease that contributes to neurological disorders in infected animals, in addition to causing substantial economic losses in production livestock (1). *Sarcocystis* is also an important protozoan that causes sarcocystosis, a disease that affects animals, including birds (2). It is considered a zoonotic disease, meaning it can be transmitted between humans and animals (3). Poultry is of great nutritional importance to humans because its meat contains a high percentage of vitamins, especially water-soluble vitamins and vitamin B (4). Livestock, especially poultry, is important to humans because it contributes to raising the economic standard and community development (5). The poultry industry is one of the fastest-growing agricultural sectors, characterized by a short production cycle and a high capacity to utilize

agricultural byproducts, which help produce a large share of meat and eggs (6). Infection with *Sarcocystis* can cause economic losses due to bird mortality and the high costs of treatment, prevention, and control (7).

Materials and Methods

The current study was conducted from October 2025 to March 2026 in Diwaniyah Governorate, Iraq. The study examined 150 birds, including wild pigeons, domestic chickens, and ducks, with 50 of each species. Samples were collected from the governorate centre and several of its districts and sub-districts. Histological samples were obtained from the oesophagus, breast muscles, and thighs after dissection and preserved under suitable laboratory conditions for parasitological, molecular, and histopathological examination.

Macroscopic examination was performed to detect visible tissue cysts of the *Sarcocystis* parasite, while



microscopic examination was achieved using pepsin digestion, slide crushing, and garlic press techniques. Positive samples were stained with Giemsa stain and examined under a light microscope to detect the slow-producing stage, bradyzoites. Histopathological examination was performed on samples fixed in 10% formalin buffer. These samples were then routinely processed histologically, sectioned at 5 μm thickness, and stained with hematoxylin - eosin (H&E).

For molecular analysis, DNA was extracted from positive tissue samples using FAVORGEN commercial extraction kits according to the manufacturer’s instructions. DNA concentration and purity were measured using a NanoDrop spectrophotometer. Nested-PCR was used to target the *Sarcocystis* spp. Specific primers were used. Gene amplification products were analyzed by agarose gel electrophoresis, and the resulting bands were then exposed to UV light. Some PCR products were subjected to genomic sequencing and phylogenetic analysis to determine the genetic relationships between local isolates and internationally recognized *Sarcocystis* species.

The primers specific to the SrRNA18 gene, listed in Table 1, were used to detect *Sarcocystis*.

Results

Macroscopic and Microscopic Infection Rates of *Sarcocystis*

The results of the current study showed variation in the gross and microscopic infection rates of the *Sarcocystis* among the studied bird species, which included wild pigeons, domestic chickens, and ducks. The total number of birds examined was 150, with 50 birds of each species. The macroscopic examination revealed 9 infections out of the total samples examined, representing an overall infection rate of 6%. Wild pigeons recorded the highest macroscopic infection rate at 10%, with 5 infections out of 50 birds. Domestic chickens and ducks each recorded an equal infection rate of 4%, with 2 infections each.

Statistical analysis showed no significant differences in gross infection rates among the bird species at the $P \leq 0.05$ level, with a chi-squared value of $X^2 = 2.12$ and a probability value of $P = 0.345$.

Microscopic examination revealed a significantly higher infection rate compared to visual inspection. A total of 48 microscopic infections were detected out of 150 birds, representing 32% of the total. Wild pigeons recorded the highest infection rate at 36% (18 infections), followed by domestic chickens at 32% (16 infections), and then ducks at 28% (14 infections). Statistical analysis showed no significant differences in infection rates among the studied bird species, with a chi-squared value (X^2) of 0.735 and a P -value of 0.692.

The results of the microscopic examination showed a significant increase in infection rates among the studied bird species. When comparing the percentages of gross and microscopic infections within each bird species, significant differences were observed. Microscopic infections were more prevalent than gross infections in all studied species. The chi-square value (X^2) was 9.54 for wild pigeons ($P = 0.002$), 13.27 for domestic chickens ($P \leq 0.001$), and 10.71 for ducks ($P = 0.001$). Overall, the results showed highly significant differences between the gross and microscopic examination methods (chi-square = 32.94, $P \leq 0.001$). This indicates that microscopic examination was more effective in detecting infection than gross examination, as shown in Table 2 and Figure 1:

Molecular diagnosis

Molecular testing using nested polymerase chain reaction (PCR) for the *Sarcocystis* showed positive results in all three bird species studied: wild pigeons, domestic chickens, and ducks. The molecular diagnosis relied on amplifying a specific segment of the parasite’s genetic material. The positive genetic bands appeared at the expected molecular size of approximately 622 base pairs, confirming the presence of the parasite in the molecularly

Table 1. Primers used to detect *Sarcocystis* in the study

Primer	Primer size and nucleotide sequence		Size
PCR gene primer	Forward	5 - GCACCTGATGAATTCTGGCA-3'	622 bp
	Reverse	5- CACCACCCATAGAATCAAG-3'	
Nested PCR gene primer	Forward	5'TGGATAACCGTGGTAATTCTATG-3'	456 bp
	Reverse	5'TCCCTATTAATCATTACTTCAGTCCTA3'	

Table 2. The numbers and percentages of macroscopic and microscopic infections of the *Sarcocystis* in the studied bird species

Sample type	No. Birds	Macroscopic infection	Percentage	Microscopic infection	Percentage	X^2	P
Wild pigeons	50	5	10	18	36	9.54	0.002**
Domestic chickens	50	2	4	16	32	13.27	<0.001**
Ducks	50	2	4	14	28	10.71	0.001**
Total	150	9	6	48	32	32.94	<0.001**
X^2		0.735					
P		0.345*		0.692*			

*Comparison of macroscopic lesions between species: $X^2 = 2.12$, $P = 0.345$

Comparison of microscopic lesions between species: $X^2 = 0.735$, $P = 0.692$

* No significant differences at the probability level ($P < 0.05$).

** Significant differences at the probability level ($P < 0.05$).

tested samples.

A total of 15 samples were molecularly tested, with 5 from each of the studied bird species, using primers specific to the 18S rRNA gene. The results showed that wild pigeons tested two of the five samples, representing 40%. Domestic chickens also recorded two positive cases out of five tested samples, also representing 40%. Ducks, however, recorded one positive case out of five tested samples, a 20% rate.

Although there was a numerical difference in molecular detection rates among the bird species, with the highest rates observed in wild pigeons and domestic chickens compared to ducks, the statistical analysis did not reveal significant differences among the studied species. The chi-square test value was 0.798×2 , and the probability value (P) was 1, indicating that observed differences in molecular infection rates were not statistically significant, with $P < 0.05$.

Molecular examination using nested polymerase chain reaction (PCR) confirmed the presence of the *Sarcocystis* in several of the tested samples, as evidenced by the appearance of clear amplification bands at the predicted molecular locus of approximately 622 base pairs. The appearance of these bands at the specified size is a positive indicator of the success of the amplification process and the presence of the parasite's genetic material in the positive samples. The gel electrophoresis image showed differences between the tested samples, with the target molecular band present or absent, as evidenced by the presence or absence of positive bands across several lanes. In contrast, the remaining samples did not show amplification at the required molecular size (as shown in Figure 2).

This result is consistent with the molecular analysis data shown in Table 3, which demonstrated positive infections in all three studied bird species.

Histopathological changes

Histopathological examination of samples from birds infected with the pineal cyst parasite *Sarcocystis* was performed to characterize histological changes, assess infection severity, and identify the locations of parasitic cysts within the examined tissues. The histological study included samples with macroscopic or microscopic lesions, particularly in muscle tissue, from areas of infection previously identified in this study in wild

Table 3. The molecular infection rates of the *Sarcocystis* pineal cyst parasite in the studied bird species

Birds species	No. of samples	No. of infection	Percentage
Wild pigeon	5	2	40
Domestic chickens	5	2	40
Ducks	5	2	20
χ^2			0.798
P			1*

*No significant differences ($P \leq 0.05$).

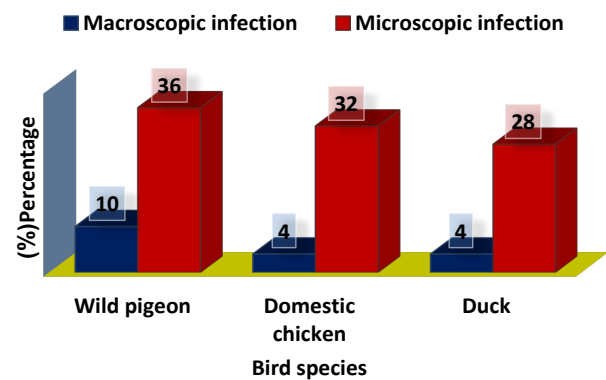


Figure 1. Diagram represent of macroscopic and microscopic infection(%) in different species of birds

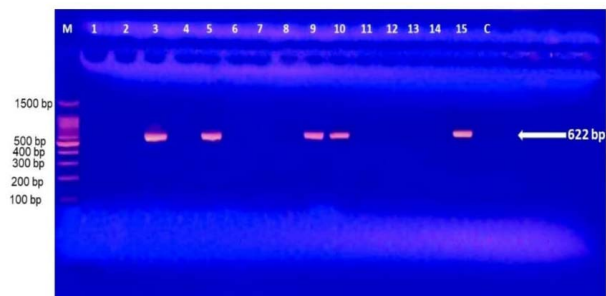


Figure 2. The results of the nested polymerase chain reaction (PCR) for the detection of the *Sarcocystis* in the studied bird samples. The bands visible at the 622 pb molecular size represent 3,5,9,10 and 15 positive samples, and the M- indicates the DNA ladder

pigeons, domestic chickens, and ducks. The histological examination relied on the study of microscopically stained tissue sections to track changes in tissue structure and determine their correlation with the presence of parasitic cysts within the infected tissues. The importance of this examination lies in clarifying the parasite's pathological effects at the histological level, complementing the results of macroscopic and microscopic examinations, and supporting the molecular findings reported in this study.

Histological examination focused on identifying parasitic cysts within or surrounding muscle fibers, as well as observing associated pathological changes such as muscle fiber rearrangement and local inflammatory infiltration. Histopathological examination of *Sarcocystis*-infected specimens revealed clear changes in the oesophagus, pectoral muscles, and thigh muscles. The most prominent findings were the appearance of parasitic structures with spherical, round, or oval shapes within the tissues, accompanied to varying degrees by inflammatory changes and structural disturbances in the affected tissue. These were further accompanied by dense inflammatory cellular infiltration in the surrounding areas, along with a marked disturbance of the local histological structure. Some sections also showed extensive inflammatory clusters within the connective tissue near the mucosa, with variations in the shape and arrangement of the lining cells in the affected areas. The parasitic structures within the tissue appeared as oval to round bodies surrounded by a distinct wall, with varying degrees of inflammatory cellular response in some sections, indicating a localized

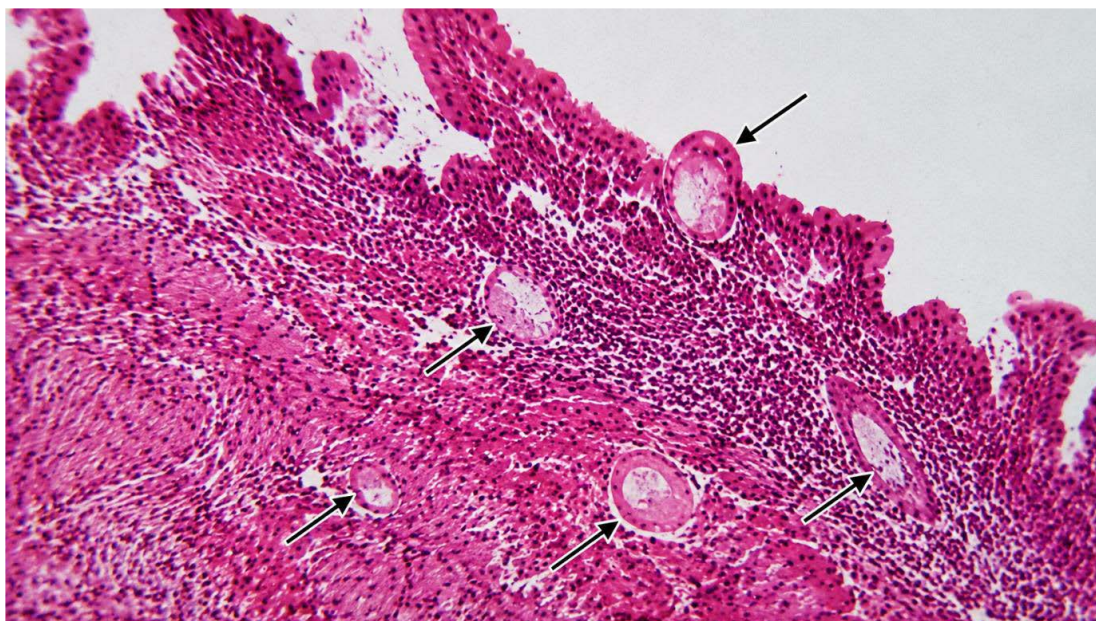

Figure 3. A histological section taken from the esophagus of a wild pigeon infected with microscopic *Sarcocystis*, with dense inflammatory cellular infiltration in the areas surrounding the cysts. The arrowheads indicate the locations of the pineal cysts. The section was examined at (40x and eosin and hematoxylin stain (H& E).

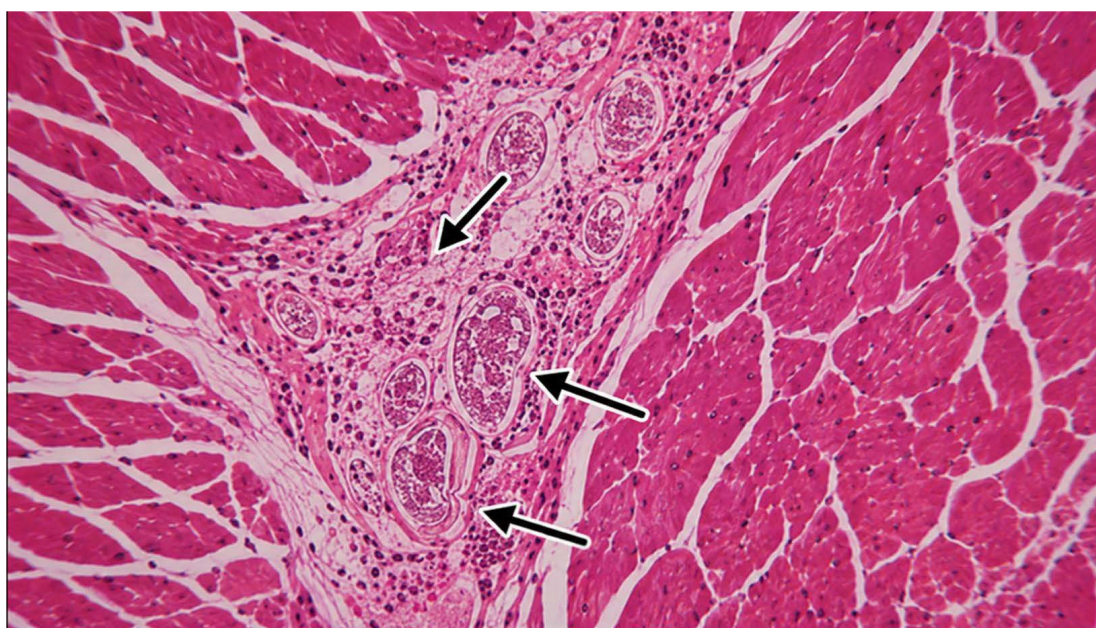

Figure 4. A histological section of the chest muscle of a domestic chicken infected with *Sarcocystis*, showing numerous parasitic cysts distributed among the muscle fibers with significant inflammatory infiltration affecting the tissue structure. The arrowheads indicate the locations of *Sarcocystis*. (40x eosin and hematoxylin H&E).

histological reaction associated with the infection. These results illustrate the pathological effect of the *Sarcocystis* parasite in esophageal tissue, as shown in [Figures 3 & 4](#).

Discussion

The results of the current study showed an overall macroscopic infection rate of *Sarcocystis columbae* (6%), with the highest rate recorded in wild pigeons (10%) compared to domestic chickens and ducks (4% each), without any statistically significant differences between the bird species. The high infection rate in wild pigeons may be attributed to their environmental behavior and

continuous exposure to sources of pollution that harbor the parasite’s infectious stages. This result is consistent with (8), who reported that *Sarcocystis columbae* was detected in wild pigeons at a rate of 11.1%, a percentage close to that of the current study.

The lower macroscopic infection rates in domestic chickens and ducks may be since some infections remain microscopic and do not form cysts visible to the naked eye. (9) reported an 8.8% infection rate with *Sarcocystis wenzeli* in chickens, indicating variations in infection rates among different bird species. The results for ducks in the current study are similar to those reported by

Prakas *et al.* (8), with gross infection rates ranging from 3.1% to 8.7% across geographic regions, bird species, and study seasons. The discrepancy between the results of the current study and some previous studies may be attributed to differences in environmental and geographic conditions, bird species, diagnostic methods used, and the varying stages of parasitic cyst development at the time of examination. Relying solely on gross examination may result in lower detection rates than microscopic examination.

The results of the current study showed that microscopic examination is superior to macroscopic examination for detecting infection with the pine cyst parasite *Sarcocystis*. The overall microscopic infection rate reached 32%, compared to only 6% in macroscopic examination, confirming the high efficiency of microscopic examination in detecting infections not visible to the naked eye. Wild pigeons had the highest microscopic infection rate at 36%, followed by domestic chickens at 32% and ducks at 28%. The high microscopic detection rates are attributed to the ability of the examination methods, particularly pepsin digestion, to release the microscopic parasite stages from infected muscle tissue, enabling the diagnosis of microscopic infections that cannot be observed with the naked eye. These results are consistent with those of (10) in Egypt, where the study recorded a clear increase in microscopic infection rates compared to macroscopic examination, reaching 84% in little grebes, with no macroscopic infections recorded. The current study is also consistent with the results of (9) in China, which confirmed the superiority of microscopic examination in diagnosing *Sarcocystis* in chickens, despite the difference in the infection rates recorded between the two studies, which may be related to the difference in environment, type of birds, and diagnostic methods used.

The results of the molecular study using Nested Polymerase Chain Reaction (PCR) showed molecular evidence of *Sarcocystis* pineal cyst infection in 5 of 15 samples tested. These included two positive infections each in wild pigeons and domestic chickens (40% each) and one positive infection in ducks (20%). This result confirms the importance of molecular testing in supporting the diagnosis of *Sarcocystis* pineal cyst infection, particularly in cases where the parasitic cysts may be morphologically similar or difficult to differentiate based solely on macroscopic or microscopic examination.

The results of the current study are similar to those of a study by (11) in Germany, which used nested PCR to detect *Sarcocystis calchasi* infection in pigeons. That study reported an infection rate of 27.8% in the homing pigeons tested, confirming the effectiveness of molecular techniques for detecting infections in bird species, even at low levels of infestation. The current study also aligns with a study by (12) in Brazil, which found that Nested-PCR molecular testing revealed *Sarcocystis* infection in 5.61% of the birds tested.

On the other hand, the results of the current study differed from those of (8), conducted in Lithuania on wild

ducks. In their study, the infection rate with the *Sarcocystis rileyi* was high in some duck species, exceeding 40% during the study period. This difference may be attributed to the species of birds studied, environmental conditions, host species, variations in sample size, and the diagnostic methods used in molecular examination.

The results of these previous studies align with modern trends in *Sarcocystis* research, where the use of molecular techniques, particularly polymerase chain reaction (PCR) and genetic analysis, has become essential for diagnosing the parasite and differentiating between its species with greater accuracy and efficiency compared to traditional methods. (13) also adopted this approach. Molecular testing was used to characterize *Sarcocystis wenzeli* in chickens, using multiple genetic loci to confirm the parasite species. (14) also employed this technique to study the genetic sequences of *Sarcocystis rileyi* isolated from ducks, thereby allowing the determination of its genetic relationship to closely related species within the same genus. The positive results recorded in the current study may be attributed to the higher sensitivity of molecular diagnostics compared to some traditional testing methods.

The results of the current histopathological examination revealed the presence of *Sarcocystis* pineal cysts within the histological sections of the esophagus, chest muscles, and thigh. These cysts were accompanied by varying degrees of inflammatory infiltrate, along with localized disruption of the organization of muscle fibers and surrounding tissues. These changes indicate a direct pathogenic effect of the parasite within the infected tissues, particularly when a clear inflammatory response in the surrounding areas accompanies parasitic cysts. The histological lesions were concentrated in skeletal muscles, reflecting the ability of these tissues to harbor the parasite's cystic stages and allow for their development within muscle cells.

The results of the current study are consistent with those reported by (15) regarding the occurrence of myositis and histological changes associated with *Sarcocystis* infection. They are pigeons, and are also consistent with the results of (16-18), which indicated the presence of parasitic cysts accompanied by inflammatory infiltration in the skeletal muscles and myocardium of infected birds, thus confirming the pathological role of the parasite in causing local inflammatory lesions and structural changes in infected muscle tissues.

Conclusion

This study concludes that microscopic examination using pepsin digestion is the most efficient and reliable diagnostic tool in conventional laboratories. At the same time, molecular and genetic analysis remains the cornerstone for accurate qualitative classification of parasite isolates. These results highlight the critical importance of integrating microscopic, histological, and molecular examinations to ensure a comprehensive and accurate diagnosis of *Sarcocystis* in birds.

Acknowledgments

The authors would like to express their sincere gratitude to the

staff of the department of biology and College of Education, University of Al-Qadisiya and molecular biology lab. for providing the laboratory facilities and administrative support necessary to complete the study.

Authors' Contribution

Conceptualization: Khaled Thamer Alshaebani, Hayder Akriem Muslim

Data curation: Hayder Akriem Muslim

Formal analysis: Hayder Akriem Muslim, Khaled Thamer Alshaebani

Investigation: Hayder Akriem Muslim

Methodology: Hayder Akriem Muslim, Khaled Thamer Alshaebani

Project administration: Khaled Thamer Alshaebani

Resources: Khaled Thamer Alshaebani, Hayder Akriem Muslim

Supervision: Khaled Thamer Alshaebani

Validation: Khaled Thamer Alshaebani, Hayder Akriem Muslim

Visualization: Hayder Akriem Muslim

Writing—original draft: Hayder Akriem Muslim

Writing—review & editing: Khaled Thamer Alshaebani, Hayder Akriem Muslim

Competing Interests

The authors declare no competing interests, financial or otherwise.

Ethical Approval

This study was approved by the Institutional Ethical Committee of the College of Education, University of Al-Qadisiyah, Iraq (Approval No.14623 in 13/6/2023).

Funding

No funding.

References

- Fayer R, Esposito DH, Dubey JP. Human infections with *Sarcocystis* species. *Clin Microbiol Rev* 2015;28(2):295-311. doi:10.1128/cmr.00113-14
- Dubey JP, Calero-Bernal R, Verma SK, Mowery JD. Pathology, immunohistochemistry, and ultrastructural findings associated with neurological sarcocystosis in cattle. *Vet Parasitol* 2016;223:147-52. doi:10.1016/j.vetpar.2016.04.025
- Shnawa BH, Swar SO. Sarcocystosis in meat-producing animals: an updating on the molecular characterization. In: *Veterinary Pathobiology and Public Health*. 1st ed. Unique Scientific Publishers; 2021. p. 144-51.
- Górska-Warsewicz H, Laskowski W, Kulykovets O, Kudlińska-Chylak A, Czacotko M, Rejman K. Food products as sources of protein and amino acids—the case of Poland. *Nutrients* 2018;10(12):1977. doi:10.3390/nu10121977
- Sainsbury D. *Poultry Health and Management*. 2nd ed. London: Granada Publishing Ltd; 1984. p. 186.
- Mottet A, Tempio G. Global poultry production: current state and future outlook and challenges. *Worlds Poult Sci J* 2017;73(2):245-56. doi:10.1017/S0043933917000071
- Attia MM, Yehia N, Mohamed Soliman M, Shukry M, El-Saadony MT, Salem HM. Evaluation of the antiparasitic activity of the chitosan-silver nanocomposites in the treatment of experimentally infested pigeons with *Pseudolynchia canariensis*. *Saudi J Biol Sci* 2022;29(3):1644-52. doi:10.1016/j.sjbs.2021.10.067
- Prakas P, Butkauskas D, Sruoga A, Švažas S, Kutkienė L. Identification of *Sarcocystis columbae* in wood pigeons (*Columba palumbus*) in Lithuania. *Vet Med Zoot* 2011;55(77):33-9.
- Chen X, He Y, Liu Y, Olias P, Rosenthal BM, Cui L, et al. Infections with *Sarcocystis wenzeli* are prevalent in the chickens of Yunnan province, China, but not in the flocks of domesticated pigeons or ducks. *Exp Parasitol* 2012;131(1):31-4. doi:10.1016/j.exppara.2012.02.022
- El-Dakhly KM, Arafa WM, Hussein NM. Morphological and molecular identification of *Sarcocystis* sp. from the little grebe, *Tachybaptus ruficollis* (Aves: Podicipediformes), for the first time in Egypt. *Beni Suef Univ J Basic Appl Sci* 2022;11(1):21. doi:10.1186/s43088-022-00205-3
- Parmentier SL, Maier-Sam K, Failing K, Gruber AD, Lierz M. High prevalence of *Sarcocystis calchasi* in racing pigeon flocks in Germany. *PLoS One* 2019;14(4):e0215241. doi:10.1371/journal.pone.0215241
- Alves ME, Fernandes FD, Bräunig P, dos Santos HF, Sangioni LA, Vogel FS. Molecular detection of *Sarcocystis* spp. in the breast muscle of captive birds from the southern region of Brazil. *Semin Ciênc Agrár* 2023;44(1):135-46. doi:10.5433/1679-0359.2023v44n1p135
- Pan J, Ma C, Huang Z, Ye Y, Zeng H, Deng S, et al. Morphological and molecular characterization of *Sarcocystis wenzeli* in chickens (*Gallus gallus*) in China. *Parasit Vectors* 2020;13(1):512. doi:10.1186/s13071-020-04390-x
- Gjerde B. Molecular characterisation of *Sarcocystis rileyi* from a common eider (*Somateria mollissima*) in Norway. *Parasitol Res* 2014;113(9):3501-9. doi:10.1007/s00436-014-4062-y
- Olias P, Gruber AD, Kohls A, Hafez HM, Heydorn AO, Mehlhorn H, et al. *Sarcocystis* species lethal for domestic pigeons. *Emerg Infect Dis* 2010;16(3):497-9. doi:10.3201/eid1603.090860
- Ushio N, Watanabe K, Chambers JK, Shibato T, Nakayama H, Uchida K. *Sarcocystis calchasi* encephalitis in a rock pigeon. *J Vet Med Sci* 2015;77(11):1523-6. doi:10.1292/jvms.15-0176
- Garedaghi Y, Olmedo-Juárez A. Investigation of the status of infection of minced beef with *Sarcocystis* parasite in samples collected from butchers in Tabriz. *Int J Med Parasitol Epidemiol Sci* 2023;4(1):25-9. doi:10.34172/ijmpes.2023.05
- Garedaghi Y, Firouzvand Y, Luca I. Prevalence of endoparasites and their zoonotic significance in wild rabbits of Ahar city, Iran. *Am J Anim Vet Sci* 2022;17(1):31-4. doi:10.3844/ajavsp.2022.31.34

© 2026 The Author(s); This is an open-access article distributed under the terms of the Creative Commons Attribution License (<http://creativecommons.org/licenses/by/4.0>), which permits unrestricted use, distribution, and reproduction in any medium, provided the original work is properly cited.