

Case Report



# A Case Report of Renal *Hydatid Cyst* in a 16-Year-Old Patient in Bonab, Iran

Yagoob Garedaghi<sup>1\*</sup>, Patrice Bouree<sup>2,3</sup>

<sup>1</sup>Department of Parasitology, Faculty of Veterinary Medicine, Tabriz Medical Sciences, Islamic Azad University, Tabriz, Iran

<sup>2</sup>Tropical Department, Institute Alfred Fournier, 75014 Paris, France

<sup>3</sup>Department of Infectious Diseases, Hôtel-Dieu Hospital, Paris, France

## Abstract

**Introduction:** Hydatidosis is a worldwide zoonotic disease caused by the larval stage of *Echinococcus granulosus*. Most cases of hydatid cysts have been reported from the liver and lungs. This study reported a case of a renal hydatid cyst in a 16-year-old patient.

**Case Report:** The patient was a 16-year-old boy from Bonab, East Azerbaijan province, who presented to the physician due to pain in the right side during urination. The CT scan showed a 34 × 41 mm cystic mass calcified in the middle of the right kidney. The patient underwent surgery successfully, and pathological findings confirmed the existence of cysts.

**Conclusion:** The findings demonstrated that the age of the renal hydatid cyst is decreasing and can be considered as many problems for the health of children and society, and any organ of the body can be attacked with *E. granulosus*. Therefore, the hydatid cyst should be suspected by observing any adhesive space in the kidney. The calcified hydatid cyst has been rarely reported in a 16-year-old boy.

**Keywords:** Hydatid cyst, Kidney, Bonab, Iran

Received: December 15, 2021, Accepted: December 24, 2021, ePublished: January 1, 2022

## Introduction

Hydatidosis is a worldwide disease that is caused by the larval stage of *Echinococcus granulosus* tapeworms. Adult worms live in the intestines of canines, and humans become infected with hydatid cysts through direct contact with infected dogs, eating food, and water contaminated with the parasite's eggs (1,2).

Epidemiologically, human infection with the hydatid cyst is more common in areas where livestock is common, and human contact with dogs and livestock provides the basis for infection (3). Factors such as age, occupation, religion, customs, and habits of people play a major role in the transmission and spread of the disease. For example, due to more contact of children with dogs or some occupations such as shepherds, tanners and farmers are more prevalent or people who have more contact with dogs are more susceptible to infection (4,5).

Hydatid cysts are common in many parts of Asia, Europe, South America, and Australia, and are most common in agricultural and livestock areas. The endemic region of hydatidosis is the Middle East, but the disease is also present in India, Africa, Southern United States, New Zealand, and Australia. Iran has a high prevalence of hydatid cysts among Middle Eastern countries so that it

is the most important parasitic worm disease in Iran (6).

The most common organs affected by this parasite are the liver (about 60%) and lung (about 20%), respectively. 13-15% of the liver and lungs are infected with a hydatid cyst; at the same time, this cyst can rarely develop in the brain, heart, kidneys, urethra, spleen, fallopian tubes, pancreas, and muscles (7).

## Case Report

The patient was a 16-year-old boy from Bonab, East Azerbaijan province, who was referred to Bonab Medical Clinic due to pain in his right side while urinating. This pain bothered the patient 15 days before the visit. On examination by the physician, the patient had a normal blood pressure of 12 mm Hg and a normal heart rate. However, a palpable mass was felt on the right side near the kidney. To correctly diagnose the disease, the patient was referred to a paraclinical laboratory for blood and urine tests and the radiology department for a CT scan. In the patient's blood test, hemoglobin (13 mg/dL), white blood cells (5200 cells/mL), red blood cells ( $4.5 \times 10^6$  cells/mL), and eosinophil cells (5%) were reported, but on CT scan images of the lesion, a circular cyst (34 × 41 mm) was shown to be calcified in the middle of the right kidney.



The patient underwent surgery in the hospital, and the surgery was successfully performed on the patient. The calcified cyst was removed by a hospital renal and urinary tract surgeon.

The germinal layers of the hydatid cyst were observed in pathology findings, and the sample was referred to the laboratory for a detailed study of the contents of the cyst. In the laboratory examination, a hydatid cyst was confirmed by observing protoscolices and calcareous bodies (Figure 1).

### Discussion

Due to the very low prevalence of hydatid cysts in the kidney, a preoperative diagnosis should be made with great care. Hydatid cysts often affect the liver and lungs, and in an unusual location, they can cause serious diagnostic problems. They require serious diagnostic tools and should be isolated from neoplasm-origin cysts, lesions, and cysts around the pancreas, and pseudo-cysts around the kidney, which are more common because correct diagnosis and prevention of incorrect treatment plans are essential (8,9).

Hydatid cyst is very rare in the kidney. Renal hydatid cysts can cause hematuria or flank pain. Glomerulonephritis, nephrotic syndrome, and secondary amyloidosis have been reported as well. Cystic rupture can cause anaphylactic shock (10).

The aim of this study was to report a case of a calcified renal hydatid cyst in a 16-year-old patient.

In a review study conducted by Fekak et al, about 90 cases of renal hydatid cysts were mostly reported in women with a mean age of 36 years (11).

In another systematic study conducted in 2010, the incidence of hydatid cysts of the kidney was found in 10 cases, mostly in women with a mean age of 9 years (12).

These statistics show that the age of the onset of the renal hydatid cyst is decreasing, and this issue can have many problems for the health of children and the community (13). The present report is consistent with recent studies in terms of age but not gender.

Hydatid cyst is difficult to treat due to the spread of the cyst and its unlimited limits. Some drugs such as

mebendazole and albendazole have improved in cases where the cysts are small and limited, but they are not responsive in all cases. However, these drugs can certainly cause cysts to shrink in size, and since surgery is the only definitive treatment, they can minimize the risk of surgery (14,15).

What is important in surgery for an old cyst is to avoid removing the fibrous membrane that forms as a result of the reaction of the host tissue around the cyst because it increases the risk of bleeding, but in young cysts, the membrane must be removed for faster tissue repair (16,17).

### Conclusion

Overall, the findings revealed that hydatidosis can invade any organ of the body; hence it should be diagnosed in different ways such as clinical examinations, laboratory tests, CT scans, magnetic resonance imaging (MRI) scans, and ultrasounds in each swollen soft tissue of patients living in endemic areas, and the patient should be further examined in this regard. The following measures should be taken to control and prevent hydatid cysts:

Observance of personal and environmental hygiene, disinfection of vegetables, enclosing vegetable farms, the extermination of cyst-infected organs when slaughtering livestock, feeding antiparasitic drugs to registered dogs and herds, lack of contact with dogs, and treatment of infected registered dogs. The other measures are the elimination of stray dogs, slaughter of livestock in sanitary slaughterhouses, slaughter of livestock at younger ages (prevention of cyst enlargement), hygienic disposal of infected viscera, lack of feeding dogs with abalone residues, and public education on how to transmit and spread the disease.

### Acknowledgments

The authors of the article thank the hospital and laboratory personals for providing valuable practical assistance to us in the present study.

### Author Contributions

YG presented the study proposal and wrote the manuscript and PB edited the final version of the manuscript.

### Conflict of Interests

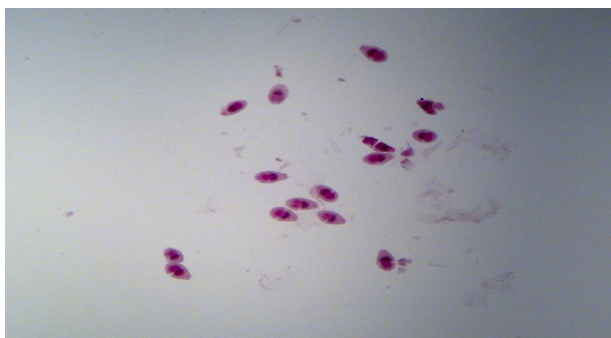
The authors declare that they have no conflict of interest.

### Ethical Issues

Informed consent was obtained from the parents of the patient for publication of this report.

### References

1. Khalifa R, Nasser F, Elsetouhy A, Farag I. Hydatid cyst of the neck. A case report and literature review. *Egypt. J. Ear Nose Throat Allied Sci.* 2016;17(2):103-5. doi: [10.1016/j.ejenta.2016.01.002](https://doi.org/10.1016/j.ejenta.2016.01.002).
2. Rabani SMR, Arefkhah N, Hosseini SA, Ngintaji M. Report hydatid cyst renal in patient 9 old years. *Armaghane Danesh.* 2012;17(2):181-6. [Persian].
3. Goyal P, Ghosh S, Sehgal S, Panda I, Kumar A, Singh S, et



**Figure 1.** Microscopic View of a Pathology Specimen of Kidney Tissue Showing the Presence of Scolex in the Cyst Fluid

- al. Primary multilocular hydatid cyst of neck with unique presentation: a rare case report and literature review. *Head Neck Pathol.* 2014;8(3):334-8. doi: [10.1007/s12105-013-0502-8](https://doi.org/10.1007/s12105-013-0502-8).
4. Çelik C, Şaşmaz MF, Ucan H. Spinal hydatid cyst: review. *Türkiye Klinikleri tıp Bilimleri Dergisi.* 2010;30(3):1073-7.
  5. Geramizadeh B. Unusual locations of the hydatid cyst: a review from Iran. *Iran J Med Sci.* 2013;38(1):2-14.
  6. Nandy M, Chakrabarti A, Mallik S. Hydatid disease presenting as multiple cystic swelling in the right supraclavicular region. *Asian Pac J Trop Dis.* 2012;2(6):490-1. doi: [10.1016/s2222-1808\(12\)60108-x](https://doi.org/10.1016/s2222-1808(12)60108-x).
  7. Nourjah N, Sahba G, Baniardalani M, Chavshin A. Study of 4850 operated hydatidosis cases in Iran. *Southeast Asian J Trop Med Public Health.* 2004;35(1):218-2.
  8. Rafiei A, Hemadi A, Maraghi S, Kaikhaei B, Craig PS. Human cystic echinococcosis in nomads of south-west Islamic Republic of Iran. *East Mediterr Health J.* 2007;13(1):41-8.
  9. Kir A, Baran E. Simultaneous operation for hydatid cyst of right lung and liver. *Thorac Cardiovasc Surg.* 1995;43(1):62-4. doi: [10.1055/s-2007-1013772](https://doi.org/10.1055/s-2007-1013772).
  10. Abu-Eshy SA. Some rare presentations of hydatid cyst (*Echinococcus granulosus*). *J R Coll Surg Edinb.* 1998;43(5):347-52.
  11. Fekak H, Bennani S, Rabii R, Mezzour MH, Debbagh A, Joual A, et al. [Hydatid kidney cyst: 90 case reports]. *Ann Urol (Paris).* 2003;37(3):85-9. doi: [10.1016/s0003-4401\(03\)00026-3](https://doi.org/10.1016/s0003-4401(03)00026-3). [French].
  12. Margi M, Benjelloul T, Cherkaoui A, Abdelhak M, Oulahyane R, Benhmamouch MN. [Hydatid cyst of the kidney in children: a retrospective study of 10 cases]. *Prog Urol.* 2010;20(2):144-7. doi: [10.1016/j.purol.2009.07.008](https://doi.org/10.1016/j.purol.2009.07.008). [French].
  13. Garedaghi Y. Prevalence and fertility of hydatid cyst in slaughtered farm animals of Tabriz city, Iran. *Life Sci J.* 2013;10(5 Suppl):190-3.
  14. Sarkari B, Naghmachi M, Azimi S, Vaezi M, Ebrahimi S. Human cystic echinococcosis in Yasuj: a survey of ten year hospital records. *Armaghane Danesh.* 2007;12(3):127-34. [Persian].
  15. Goel MC, Agarwal MR, Misra A. Percutaneous drainage of renal hydatid cyst: early results and follow-up. *Br J Urol.* 1995;75(6):724-8. doi: [10.1111/j.1464-410x.1995.tb07379.x](https://doi.org/10.1111/j.1464-410x.1995.tb07379.x).
  16. Sadeghi P, Khayatnouri M, Hashemzade Farhang H, Kaffash Elahi R. In vivo therapeutic effect of triclabendazole+levamisole on hydatid cyst in rats. *Int J Med Parasitol Epidemiol Sci.* 2020;1(1):14-16. doi: [10.34172/ijmpes.2020.06](https://doi.org/10.34172/ijmpes.2020.06).
  17. Sarkar S, Roy H, Saha P, Sengupta M, Sarder K, Sengupta M. Cystic echinococcosis: A neglected disease at usual and unusual locations. *Trop Parasitol.* 2017;7(1):51-5. doi: [10.4103/tp.TP\\_55\\_16](https://doi.org/10.4103/tp.TP_55_16).

© 2022 The Author(s); This is an open-access article distributed under the terms of the Creative Commons Attribution License (<http://creativecommons.org/licenses/by/4.0>), which permits unrestricted use, distribution, and reproduction in any medium, provided the original work is properly cited.